

Katelyn P McKey, DPT<sup>1</sup>  
Meryl J Alappattu, PT, DPT, PhD<sup>2</sup>

1. Department of Physical Therapy  
University of Florida  
PO Box 100154  
Gainesville, Florida 32610

2. Pain Research and Intervention  
Center of Excellence  
University of Florida,  
Gainesville, Florida 32610

Correspondence:  
kmckey@ufl.edu

## Physical Therapy Intervention to Augment Lymph Node Transfer Surgery for a Breast Cancer Survivor with Secondary Upper Extremity Lymphedema: A Case Report

**Background and purpose:** Lymphedema is an incurable complication of breast cancer treatment that affects roughly 20 percent of women. It is often managed via complete decongestive therapy, which includes manual lymph drainage, therapeutic compression, skin care, and exercise. Lymph node transfer is a new and expensive surgical intervention that uses one's own lymph nodes and implants them in the affected upper extremity. Previous research has investigated augmenting lymph node transfer surgery with complete decongestive therapy, but there is a lack of evidence regarding the success of focusing lymph drainage against the normal pressure gradient toward a surgical flap located on the wrist. The patient's main motivation for the surgical intervention was to alleviate her daily burden of complete decongestive therapy. The purpose of this case report was to compare the methods and results of pre-surgical complete decongestive physical therapy to a post-operation modified approach that directed lymph fluid away from the major lymphatic ducts and instead toward a surgical flap on the wrist of a patient with lymphedema. **Case Description:** A 65-year-old female presented with secondary upper extremity lymphedema following breast cancer treatment. Her circumferential measurements and L-Dex score corroborated this diagnosis, and she had functional deficits in upper extremity range of motion. She was seen for 10 visits of traditional complete decongestive therapy prior to her lymph node transfer surgery and 24 treatments of modified complete decongestive therapy over the course of six months following surgery. **Outcomes:** At six months, the patient had minor improvements in the Functional Assessment of Chronic Illness Therapy-Fatigue, Disabilities of the Arm, Shoulder and Hand questionnaire, range of motion, and upper extremity strength. However, her circumferential measurements and L-Dex scores showed a meaningful increase in limb girth. **Discussion:** The patient's smallest upper extremity volumes were documented before the operation after two weeks of complete decongestive therapy. The surgical intervention supplemented by modified complete decongestive therapy resulted in increased limb girth after six months. Although the patient was able to stop wearing her compression garment while continuing independent manual lymph drainage and upper extremity wrapping, the post-surgical intervention was not a success because the patient's circumferential measurements remained meaningfully higher than at her initial examination. Further research is needed to determine the long-term effects of this surgery when coupled with physical therapy intervention, and whether it has better outcomes than the standard conservative treatment of complete decongestive therapy alone.

**Key Words:** *decongestive, intervention, outcome*

### INTRODUCTION

Secondary lymphedema is a result of damage to lymph nodes that occurs during breast cancer treatment, either by axillary lymph node dissection or

radiation therapy.<sup>1</sup> This injury impairs the lymph nodes' ability to filter lymph, causing a buildup of the protein-rich fluid in the surrounding tissues. The incidence of developing lymphedema after breast cancer treatment

is roughly 20 percent. If an axillary node dissection is performed there is a lifelong risk for lymphedema, and symptoms may develop up to 30 years after treatment.<sup>1</sup> Lymphedema is considered a progressive disease, and if left untreated it can cause painful, fibrotic tissue, infection, and increased limb girth.<sup>1</sup> These impairments can lead to decreased function and emotional suffering,<sup>2</sup> which can impact an individual's quality of life and participation in work and leisure activities.

Physical therapists are crucial members of a patient's multidisciplinary cancer care team. Physical therapists are often utilized to prescribe exercise programs to combat cancer-related fatigue, address shoulder range of motion and strength impairments that can result from surgery and radiation, and spearhead lymphedema management.<sup>3</sup> Traditional guidelines have taken a conservative approach to managing lymphedema, and physical therapists can specialize in this treatment. Current protocols recommend complete decongestive therapy (CDT), which includes education, activity modification, manual lymph drainage, limb wrapping, and wearing compression garments to reduce limb volume.<sup>4</sup> The National Lymphedema Network recommends that medical practitioners complete 135 hours of coursework and hands-on instruction in CDT.<sup>5</sup> Several professions other than physical therapists also commonly perform CDT including physical therapy assistants, occupational therapists and assistants, nurses, massage therapists, speech therapists, medical doctors, and physician assistants.<sup>5</sup> A 2011 meta-analysis found that manual lymph drainage combined with compression therapy resulted in a small statistically significant improvement in upper extremity volume compared to compression therapy alone.<sup>6</sup>

Complete decongestive therapy is a lifelong process and requires a great deal of time and energy from the patient. Surgical intervention is a new option that may help those who are not responsive to conservative treatment to either cure the lymphedema or to better manage it with decreased reliance on CDT.<sup>7</sup> Vascularized lymph node transfer is a procedure that involves harvesting autologous lymph nodes, vasculature, and fat from the inguinal region and transplanting these structures in the affected limb. The purpose is to use one's own healthy lymph nodes to compensate for the damaged lymph nodes. A 2013 systematic review evaluated lymph node transfer

surgeries performed at several recipient sites in the upper extremity including the wrist, elbow, axilla, and the supraclavicular area. One study by Lin et al that transplanted to the wrist reported 12 of 13 patients had a mean volume reduction of 51 percent, improvement in lymph flow measured by lymphoscintigraphy, and 11 of 13 participants reported decrease in cellulitis symptoms.<sup>8</sup> Studies citing the axilla as the recipient location reported participants had a decrease in pain and upper extremity volume.<sup>7</sup> The review found overall positive results in decreasing limb size, regardless of the location of the transplanted lymph nodes.<sup>7</sup> Due to small sample size and lack of randomized controlled trials further research is necessary for more definitive conclusions about the long term effects of lymph node transfers.<sup>7</sup>

Several studies have documented continuing to utilize CDT after lymph node transfer surgery.<sup>7,9</sup> In some cases, therapy was weaned and then eventually ceased due to successful reduction in limb volume.<sup>7,9</sup> Specifically, studies using the axilla as the lymph node transfer site reported participants were able to discontinue CDT techniques between three and 12 months post surgically.<sup>7</sup> Traditionally, CDT emphasizes directing lymph fluid toward the trunk to be processed by nodes in the contralateral axilla and ipsilateral groin.<sup>10</sup> Lymph node transfer is a relatively new lymphedema treatment option, and that is a lack of understanding of how to adapt CDT to maximize the filtration potential of a lymph node flap located on the wrist. In this report, complete decongestive therapy addressed that issue by pushing fluid from proximal to distal instead of draining fluid toward the trunk. The purpose of this case report was to compare the methods and results of pre-surgical complete decongestive physical therapy to a post-operation modified approach that directed lymph fluid away from the major lymphatic ducts and instead toward a surgical flap on the wrist of a patient with lymphedema.

## CASE DESCRIPTION

### History

The patient was a 65-year-old female diagnosed with invasive ductal carcinoma of the left breast three years prior to the initial physical therapy evaluation. She underwent a lumpectomy with an

axillary dissection that included removal of 13 lymph nodes as well as adjuvant radiation and chemotherapy. Fourteen months after surgery, she developed lymphedema in her left arm while stopping a wheelbarrow from rolling into her. She had her initial examination at the physical therapy oncology clinic approximately three weeks after the injury.

The patient had a medical history of cataracts, joint pain, neck pain, hyperlipidemia, and a surgical history of tubal ligation, cataract surgery, and a melanoma excision. She was referred from a reconstructive plastic surgeon to an outpatient physical therapy clinic that specialized in oncology rehabilitation and lymphedema management. Secondary lymphedema is commonly controlled conservatively using complete decongestive therapy, but this patient was seeking surgical intervention to reduce the extensive effort this technique requires. Specifically, her goal was to decrease her daily dependence on her arm and hand compression garments. Physical therapy was utilized as a supplemental treatment to potentially maximize surgery's reduction in lymphedema volume, as well as improve upper extremity function and strength.

The patient in this case report received a lymph node transfer that used healthy lymph nodes and the superficial circumflex artery and vein from her right groin, and then transplanted them to the dorsum of her left wrist via a microsurgical anastomosis with the dorsal branch of the radial artery and cephalic vein. The ideal lymph node recipient site in the patient's affected arm was discussed with her surgeon. Other studies commonly used the axilla as the recipient location because it was the site of the impaired nodes and it was in an easily-concealed area. However, it can be difficult to find vasculature in this region that has not been damaged by dissection and radiation therapy<sup>8</sup>. The wrist was an attractive surgical site due to its healthy tissue and vasculature that would better support lymph flow and decrease the reliance on the damaged nodes located at the axilla.<sup>8</sup>

The patient received complete decongestive therapy five days a week for two weeks prior to surgery with the rationale that it would help prepare her lymph system to improve her outcomes post surgically.

## EXAMINATION

At her pre-operative initial evaluation, the patient presented with left upper extremity lymphedema, and she wore compression garments on her left arm and hand. The patient verbalized tenderness to palpation of her left arm, and she had pitting edema at the wrist with slow rebound. The examination did not reveal fibrosis or axillary cording, and sensation to light touch was intact in the affected limb. With the patient in sitting position, strength was assessed via manual muscle testing for bilateral shoulder flexion, abduction, internal rotation, and external rotation. Passive range of motion of the patient's shoulder flexion, abduction, internal rotation, and external rotation was measured with the patient in supine using a goniometer. A study of goniometric measurements in participants without shoulder pathology determined high intra-rater reliability (.86 - .91), moderate inter-rater reliability (.49 - .88), and the minimal clinical difference for two evaluators was 14 to 24 degrees.<sup>11</sup>

Circumferential measurements of both arms were taken using a tape measure with the patient seated and her arms supinated with elbows extended. Measurements were taken at the patient's hand web space, at the styloid process of the wrist, 8 cm proximal to the wrist, 16 cm proximal to the wrist, at the elbow crease, 8 cm proximal to the elbow, 16 cm proximal to the elbow, and 24 cm proximal to the elbow. A 2006 paper concluded that circumferential measurements using anatomical landmarks are a reliable measurement of lymphedema in breast cancer patients (ICC  $\geq$  0.97). It also determined circumferential measurements converted to volumes had high validity compared to the water displacement method of measuring volume ( $r = 0.98$ ).<sup>2</sup>

The patient's circumferential measurements for her hand web space were compared to a study that evaluated the figure 8 method of measuring swelling in people with ankle edema.<sup>12</sup> The minimum detectable change calculated from this study was 1.2 cm. Girth measurements were also converted to volume using a formula developed by Taylor et al.<sup>2</sup> The article determined that the minimum detectable change in volume for the left upper extremity using anatomical landmarks was 149.7 mL.

Additionally, the patient underwent an L-Dex screening for lymphedema. The L-Dex is a tool used to assess bioimpedance spectroscopy, which measures

fluid in one's tissues by sending a small electrical signal through the body. To evaluate, electrodes were placed on the dorsum of both wrists and dorsum of the right foot, and then it compared both the affected and unaffected sides.<sup>4,13</sup> An L-Dex score 10 or more units from zero indicates a lymphedema diagnosis. This tool has moderate reliability for women with lymphedema (ICC=0.69; 95% CI = 0.54 to 0.80).<sup>13</sup> The minimum detectable change calculated for the L-Dex in patients with lymphedema was 41.8 units.<sup>13</sup>

### Self-Reported Outcome Measures

The patient completed a Disabilities of the Arm, Shoulder and Hand (DASH) outcome measure. The DASH quantifies perceived difficulties in upper extremity function by having the patient rank 30 tasks from 0 (no difficulty) to 5 (unable).<sup>14</sup> Higher scores indicate greater disability. It has been validated in several populations mostly focusing on musculoskeletal disorders, and it has also been used in breast cancer survivors both with and without lymphedema.<sup>15</sup> A 2013 systematic review favored using the DASH in breast cancer survivors because it had the highest effect size for responsiveness and construct validity when compared to other upper extremity outcome measures.<sup>15</sup> The DASH successfully discerned between breast cancer survivors with and without lymphedema (ES 1.63 and 0.65), and it had moderate responsiveness when a lymphedema treatment was matched to a control (ES 0.45 and 0.71).<sup>15</sup> A study evaluated the DASH in women who had breast cancer both with and without lymphedema and determined that a minimum detectable change in this population was 9.5 points.<sup>16</sup>

Lastly, the patient was evaluated using the Functional Assessment of Chronic Illness Therapy – Fatigue (FACIT-F), a self-reported fatigue scale. The FACIT-F is made up of 13 questions related to fatigue that the patient ranks from 0 to 4 with higher values indicating greater impairment.<sup>17</sup> Research in people with cancer has shown that the FACIT demonstrated high reliability ( $\alpha = 0.96$ ) and was moderately to highly correlated with quality of life ( $r = 0.78$ ).<sup>17</sup> Research in patients with cancer was used to calculate the minimum detectable change to be 6.71 units in this population.<sup>17</sup>

Even though her manual muscle test revealed good strength in the affected shoulder, the patient's

goals for physical therapy treatment were to improve left upper extremity strength, especially in her hand, as well as ameliorate shoulder range of motion.

## EVALUATION

### Diagnosis

Lymphedema is commonly diagnosed by taking circumferential measurements of both the affected and the unaffected limbs. A positive diagnosis is made if there is more than a 2.0 cm difference when comparing sides.<sup>3</sup> This patient had a greater than a 2.0 cm difference between left and right arms from 16 cm proximal to the wrist to 8 cm proximal to the elbow. The patient's initial L-DEX score was 21.7.<sup>13</sup> Both the circumferential measurements and L-Dex values validated her diagnosis of lymphedema.

The patient had limited range of motion in her affected shoulder and mild impairment in self-reported upper extremity function. Additionally, her compression garment negatively impacted her ability to participate in work and outdoor activities. Based on findings in the initial examination, this patient was a good candidate for a physical therapy intervention that focused on reducing upper extremity volume via CDT, improving shoulder range of motion, and increasing her fitness level to help combat fatigue.

### Prognosis and Plan of Care

In addition to the patient's relatively short duration of lymphedema symptoms, several other factors contributed to her good prognosis for physical therapy treatment. She did not present with fibrosis, a clinical indicator that the lymphedema has progressed. She had good upper extremity strength and good functional use of her affected limb as indicated by her low DASH score. Obesity increases risk for developing lymphedema, and a study has shown improvement in arm volume after weight loss.<sup>6</sup> The patient's active lifestyle and normal weight positively impacted her prognosis. She demonstrated compliance with wearing her compression garment and was motivated to participate in physical therapy.

Research concerning the outcomes of surgical lymph node transfer have been favorable and with few complications, but overall there is a lack of long term follow up and high quality study designs.<sup>7</sup> Immediately

post surgery, the patient was expected to experience increased swelling in the affected limb, and the her surgeon anticipated optimal outcomes to be achieved by one year after surgery.

The physical therapy plan of care for this patient included one to five days of weekly physical therapy with a daily home regimen for six months to focus on complete decongestive therapy as well as upper extremity stretching and strengthening.

## INTERVENTION

### Complete Decongestive Therapy

The patient received complete decongestive therapy (CDT) five days a week for two weeks prior to surgery with the purpose of improving surgical outcomes. CDT consists of manual lymph drainage, compression bandaging, moderate exercise, skin care education, compression garments, and instruction on self-management.<sup>4</sup> The patient's main motivation for undergoing surgery was to manage her lymphedema without wearing a compression garment. She did not wear a compression sleeve at all after surgery, so this portion of CDT was not emphasized.

After her surgery, the patient was seen for six months of regular physical therapy for CDT. During her 10-day hospital stay, she was seen at bedside for six treatments. She returned to the outpatient clinic and was treated three times a week for the first three weeks, then once a week for weeks four to six. During that time, her circumferential measurements increased indicating her left arm swelling was worsening, so she resumed physical therapy twice a week for weeks seven to 10. She was reduced back to once a week for weeks 11 – 25.

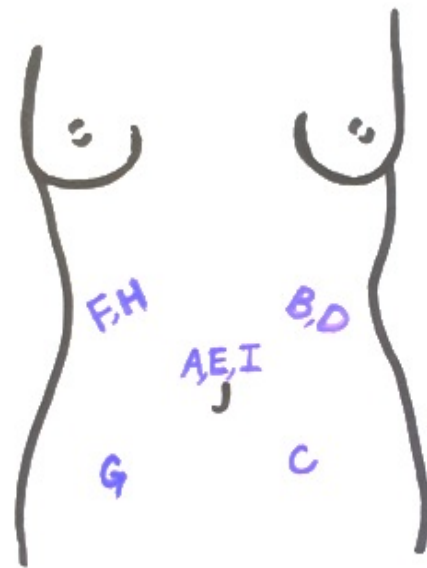
### Pre-Surgical Manual Lymph Drainage

Manual Lymph Drainage (MLD) is a hands-on technique that provides a light skin stretch to the affected area to activate lymph vessels that are close to the skin's surface. It helps remove excess fluid and promotes fluid uptake by lymph vessels in other areas of the body that are not impaired.<sup>10</sup> Clinical practice for standard manual lymph drainage of the upper extremity requires lymph to be directed toward the

trunk so that it can be filtered by the thoracic duct. Lymph fluid is also pushed toward nodes in the ipsilateral groin and contralateral axilla via watershed pathways so that it bypasses the impaired nodes and can instead be filtered by ones that are fully functioning.<sup>10</sup> Each stroke was performed seven times to achieve the best outcomes.<sup>10</sup>

The treatment always began with the patient supine with abdominal strokes to help promote uptake of lymph fluid to the thoracic duct.<sup>10</sup> She was instructed to take seven deep, diaphragmatic breaths. Then, light strokes using the palm of the hand going toward the belly button were performed medial to each anterior superior iliac spine and medial to the lower ribs seven times each bilaterally. Next several sections of the abdomen were stimulated using circular strokes and coordinated with the patient's breathing. The abdominal pattern is illustrated in figure 1.

**Figure 1. Deep Abdominal Sequence for MLD**

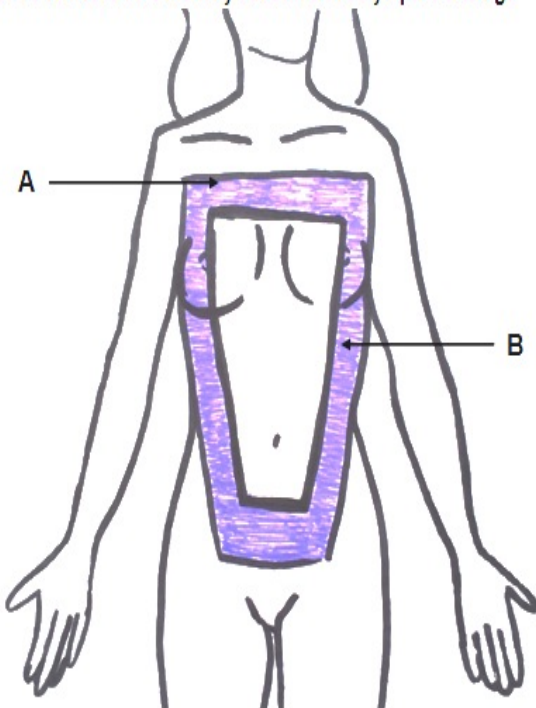


**Circular strokes were performed at each location in order from A to I.**

Next the patient's supraclavicular lymph nodes were stimulated with seven light, circular strokes. Then circular strokes in the patient's contralateral axilla were performed seven times, and fluid was pushed from left to right across the chest using strokes called stationary circles. Stationary circles is a stroke that utilized the palm of the therapist's hand to push perpendicular to the superficial lymphatic vessels to "stretch" them

open, then the therapist performed a parallel stroke to push the fluid along the pathway.<sup>10</sup> This area across the chest is the axillo-axillary anastomosis watershed pathway. Watersheds are invisible lines that represent areas of the body normally filtered by nodes in a specific location.<sup>10</sup> The cluster of lymph nodes in the left axilla normally filter fluid from the left arm as well as the left side of the upper chest and back. The anastomosis follows the watershed pathway to encourage lymph nodes in other parts of the body to process fluid that it would not naturally access.<sup>10</sup> Lymph nodes in the patient's left groin were then stimulated with seven circular strokes and fluid was pushed via stationary circle strokes from the left axilla to the left groin following the axillo-inguinal anastomosis watershed pathway. Both watershed routes are detailed in figure 2.

Figure 2. Watershed Pathways for Manual Lymph Drainage

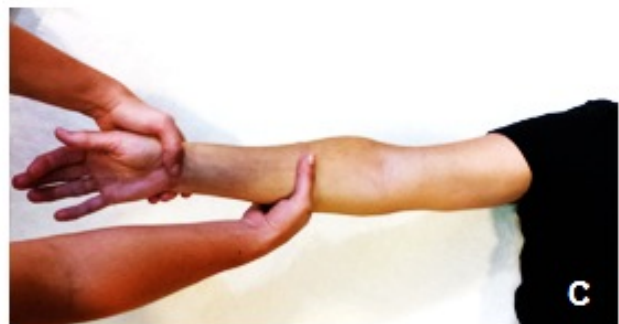
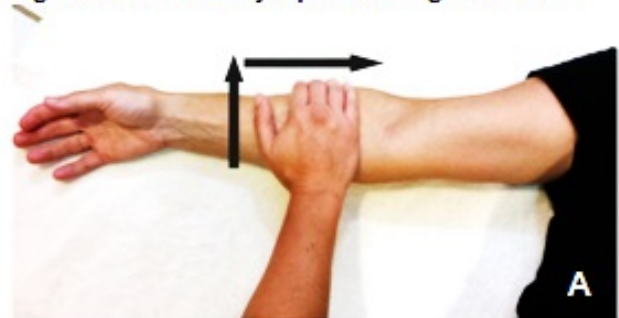
The highlighted portion (A) illustrates the axillo-axillary anastomosis. The highlighted portion (B) shows the axillo-inguinal anastomosis.

Then the patient's upper arm was drained from elbow to axilla using stationary circles. Next the forearm was drained from wrist to elbow using a scoop stroke. For this technique, the therapist's palm started on the ventral forearm, swept around to the dorsal side of the forearm, and then slid up toward the elbow. All strokes were performed seven times.

If the patient's hand was swollen, stationary circles were performed at the dorsum of the hand seven times. Then a pump stroke was performed from wrist to axilla. The pump stroke involved the therapist using the web space and palm of the hand starting in ulnar deviation and slight wrist flexion, and ending in radial deviation and slight wrist extension to push fluid from distal to proximal. Finally, a rotary stroke was performed along the axillo-axillary anastomosis and along the axillo-inguinal anastomosis. The rotary stroke started with the therapist's palm on the patient's skin, and while maintaining contact, the thumb and fingers came into opposition, then the fingers abducted and the wrist went into ulnar deviation. This sequence was performed one time. Pictures of these strokes are referenced in figures 3 and 4.

Figure 3. Manual Lymph Drainage Strokes



A – Stationary circles  
B – Scoop stroke starting phase  
C – Scoop stroke ending phase

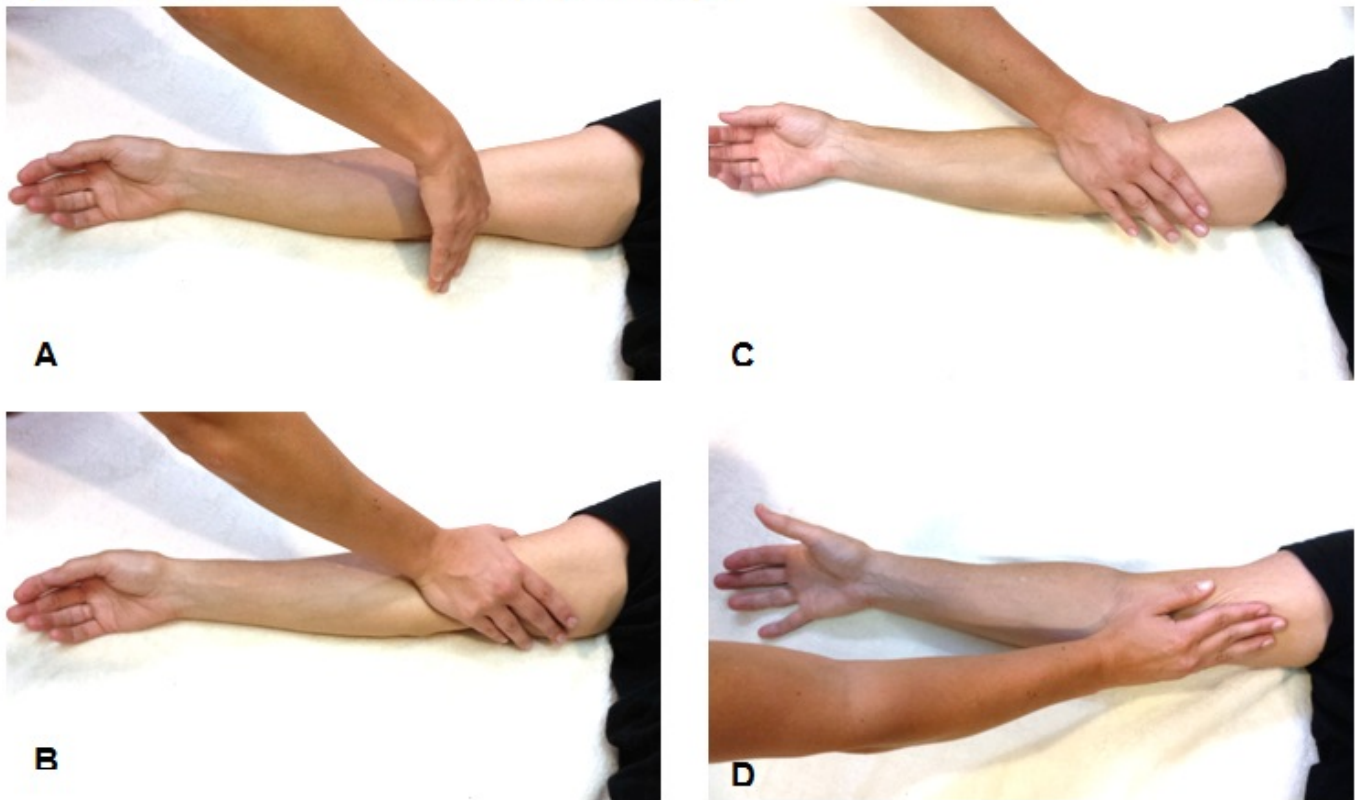


### Manual Lymph Drainage Post Surgery

The patient's surgeon opted to place her lymph node flap on the dorsum of her wrist, therefore, the focus of the decongestive therapy became to push the lymph fluid toward the newly placed healthy lymph nodes instead of following the usual protocol of draining toward the trunk. For this reason, the anastomosis was not utilized. The treatment always began as before with the patient supine performing diaphragmatic breathing and the abdominal sequence. Then the patient's supraclavicular lymph nodes were stimulated with seven light, circular strokes. Lymph

nodes in her antecubital fossa were stimulated in the same fashion. Lymph was pushed from the patient's left axilla to her antecubital fossa seven times using stationary circles. Next lymph was moved from the antecubital fossa toward the surgical flap on the dorsum of the wrist seven times using scoop strokes. Finally, the hand was drained toward the flap on the wrist with semicircular strokes with the hand elevated so that the fluid would not have to travel against gravity. The patient performed self manual lymph drainage following the same sequence using her right hand on her left arm on the days that she did not have therapy. The treatment is referenced in figures 5 and 6.

**Figure 4. Stroke Patterns in Manual Lymph Drainage**



**A – Pump stroke beginning phase  
B – Ending phase of pump stroke**

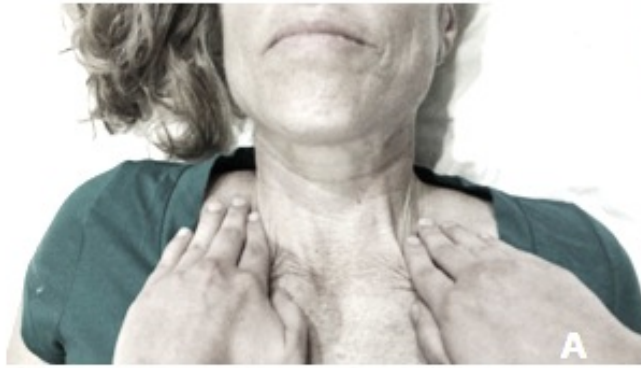**C – Beginning phase of rotary stroke  
D – Ending phase of rotary stroke**

### Compression Therapy

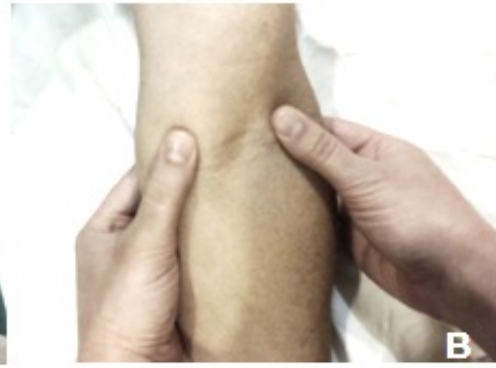Compression therapy utilizes short-stretch bandages to help maintain the effects of MLD and prevents fluid re-accumulation in the extremity.<sup>10</sup> Compression wrapping of the patient's left arm and

hand started two weeks prior to surgery, then was again resumed four weeks after surgery and continued until week 10. Wrapping occurred with the patient seated, shoulder flexed to 75 degrees, and her arm pronated with the elbow extended.

**Figure 5. Manual Lymph Drainage Sequence**



A – Stimulation of supraclavicular lymph nodes



B – Stimulation of antecubital lymph nodes

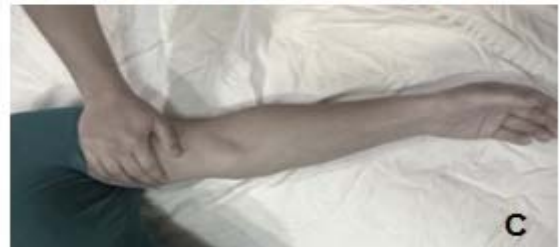The first step was to cover from palm to axilla with a soft cotton stocking liner. Then soft foam padding was wrapped in a spiral pattern for the length of the arm. Then the patient’s hand and wrist was covered with a 6 cm short stretch bandage and her forearm was covered by an 8 cm short stretch bandage both wrapped in a spiral pattern. Finally, two layers of 10 cm short stretch bandages were wrapped from mid forearm to axilla in a figure 8 pattern.

From weeks 11 – 27, the arm was wrapped in reverse with emphasis on wrapping from axilla to wrist. This technique was performed to encourage fluid to move from the proximal impaired lymph nodes to the healthy lymph nodes at the distal flap. Again, the patient donned a cotton stocking liner and foam for the length of her arm. The first layer of 6 cm short stretch bandages was wrapped in a spiral pattern going from the patient’s palm to her surgical site at her wrist. Then, subsequent layers of the 8 cm bandage started at the axilla and were wrapped going down the arm in a spiral pattern. The last two layers of compression wrapping used 10 cm bandages in a figure 8 pattern from axilla to wrist.

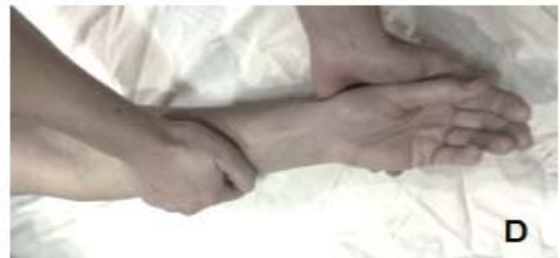The patient’s primary motivation for electing surgery was to enable her to manage her lymphedema without having to wear a compression sleeve or wrapping her upper extremity. For this reason, an upper extremity compression garment was not used as an intervention post surgery. Additionally, at 11 weeks post surgery the frequency of limb compression wrapping was reduced from daily to three times a week, and then again reduced to twice a week starting

24 weeks after surgery. The wrapping schedule is further detailed in table 1.

**Figure 6. Drainage of the Arm**



C



D



E

C – Stationary circle from axilla to elbow  
 D – Scoop stroke from elbow to wrist  
 E – Draining the hand toward the wrist



## Exercise

Research shows that people with lymphedema who participate in aerobics and strengthening get stronger and lymphedema symptoms do not worsen.<sup>16</sup> Therefore, the patient participated in a stretching and strengthening program in addition to her CDT after undergoing her operation.

As a warm up to increase her heart rate, the patient used an upper extremity cycle ergometer for 10 minutes at the beginning of therapy sessions. Starting one week prior to surgery, strengthening exercises were performed using a Theraband. With a green Theraband secured to the wall, the patient completed latissimus pulldowns and rhomboid rows while standing, doing one set of 10 repetitions for each exercise. Strengthening of shoulder external rotators was also performed while standing using a green Theraband for one set of 10 repetitions. D2 shoulder extension exercises in standing were added to the exercise regimen six weeks after surgery for two sets of 10 repetitions using the yellow Theraband. Starting 17 weeks after her surgery, the patient did pectoral stretches in standing with her forearm braced against a wall. These stretches were held for 30 seconds for two repetitions. Finally, in quadruped on the mat, the patient performed exercises using a dumbbell to strengthen her scapular stabilizers starting 18 weeks after surgery. These exercises were performed in three different positions using a two-pound dumbbell for 15 repetitions each.

These exercises were not strongly emphasized during treatment sessions due to time restraints and prioritizing CDT. They were included in a home exercise program that the patient completed two times a week while her arm was wrapped. The patient's exercises progression is included in table 2. **Skin Care**

Proper skin hygiene was emphasized because lymphedema causes a buildup of protein-rich fluid that can easily become infected.<sup>3</sup> The patient was told to avoid needles or taking blood pressure in the affected arm. In the event of minor wound to her arm, she was instructed to wash it thoroughly. The patient was also educated regarding wearing her compression wrapping during exercise or when flying on an airplane, to avoid

**Table 1. Schedule of Upper Extremity Wrapping**

Timeline	Wrapping	Frequency
<b>Initial Examination</b>	-	-
<b>2 weeks pre op</b>	2 weeks of wrapping	Worn 24 hours
<b>3 weeks post op</b>	-	-
<b>4 weeks post op</b>	1 week of wrapping	Worn 24 hours
<b>5 weeks – 10 weeks</b>	-	-
<b>10 weeks</b>	1 week of wrapping	worn 24 hours
<b>Weeks 11 - 16</b>	3 days per week reverse wrapping	worn 24 hours
<b>17 weeks</b>	-	-
<b>18 weeks</b>	Reverse wrapping – *number of days unavailable	Worn only during the day
<b>19 weeks – 20 weeks</b>	-	-
<b>21 weeks – 23 weeks</b>	Reverse wrapping 3 days each week	Worn only during the day
<b>24 – 27 weeks</b>	Reverse wrapping 2 days each week	Worn only during the day

Dash (-) = no wrapping performed

excessive heat or cold, and to avoid wearing restrictive clothing.<sup>18</sup> These are common points of education that are supported by the National Lymphedema Network, however, the literature to substantiate these recommendations is lacking.<sup>3</sup>

## Home Program

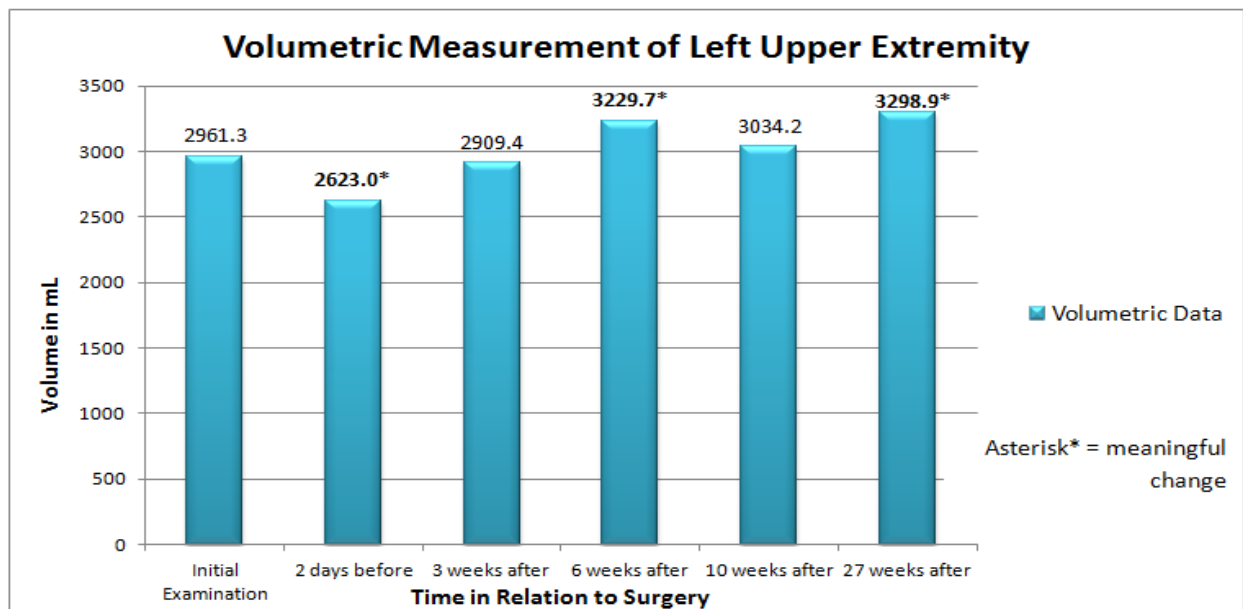
Because lymphedema is a chronic disorder, the patient's physical therapist decreased her frequency of visits as she became comfortable with performing the treatments techniques on her own. Her home program included daily self MLD, self compression wrapping that occurred between two and seven days a week, and an exercise program performed twice a week.

**Table 2. Exercise Program**

	<b>1 week before surgery</b>	<b>3 weeks after surgery</b>	<b>4 weeks after surgery</b>	<b>5 weeks after surgery</b>	<b>6 weeks after surgery</b>	<b>7 weeks after surgery</b>	<b>17 weeks after surgery</b>	<b>18 weeks after surgery</b>
Latissimus pull down	10 reps GTB	NT incision pain			2 x 10 reps GTB			2 x 10 reps BTB
Rhomboid Row	10 reps GTB	10 reps GTB					20 reps GTB	2 x 10 reps BTB
Shoulder ER	10 reps GTB	10 reps GTB						
UE Ergometer			Level 2.5 5 min forward 5 min backward	Level 4.5 5 min forward 5 min backward	Level 5.0 5 min forward 5 min backward	Level 5.0 5 min forward 5 min backward		
D2 extension					2 x 10 reps YTB	2 x 10 reps YTB	15 reps GTB	15 reps GTB
Pectoralis major stretch							2 x 30 sec	2 x 30 sec
Pectoralis minor stretch								2 x 30 sec
Quadruped								15 x each letter
TWY								2 pounds

**GTB** = green Theraband; **BTB** = blue Theraband; **YTB** = yellow Theraband; **Min** = minutes; **Sec** = seconds; **reps** = repetitions; **ER** = external rotation; **UE** = upper extremity; **NT** = not today

**Figure 8.**



**Table 3. Circumferential Measurements of Left Upper Extremity in Centimeters Over Time**

	Initial exam Right - Unaffected	Initial exam Left - Affected	2 days before surgery	3 weeks after surgery	6 weeks after surgery	10 weeks after surgery	27 weeks after surgery
Web space	19.6	19.4	19.6	20.5	20	19.6	<b>20.8 ♦</b>
Wrist	-	(assumed as 16)	16	18	19.3 <b>w</b>	18	18.8
8 cm above wrist	19.1	19.7	20.2	21.1 <b>p</b>	23.5 <b>w</b>	23.4	24.7
16 cm above wrist	24	<b>27*</b>	25.7	27.2	30.2	27.9	30.6
Elbow crease	25.3	<b>29.6*</b>	25.8	29	29.7	28.4	30.4
8 cm above elbow	28.5	<b>32.5*</b>	31.1	32.3	34	31.2	33.0
16 cm above elbow	32	32	30.7	31.3	32.2	32.7	32.1
Axilla – 47 cm above wrist	33.5	33.6	29.8	30.6	30.8	32.8	33.0

Lymphedema circumferential measurements of upper extremity taken in sitting with arm supinated

Asterisk\* = Greater than 2 cm difference indicating lymphedema

♦ = meaningful change compared to values at initial examination

P = measurement taken with post surgical dressing removed and arm pronated with elbow bent

W = wound vac dressing was worn

**Table 4. Self-Reported Outcome Measures**

	Initial examination	10 days after surgery	10 weeks after surgery	27 weeks after surgery
L-Dex	21.7	-	<b>79.1*</b>	<b>86.2*</b>
DASH	8.33	<b>50.8*</b>	-	4.17
FACIT-F	-	31	-	<b>11*</b>

Asterisk \* = meaningful change

**Table 5. Strength Over Time**

	Initial Evaluation	2 days before surgery	2 weeks after surgery	27 weeks after surgery
Shoulder flexion	R: 4+/5 L: 4+/5	R: 4/5 L: 4/5	R: 4/5 L: 4-/5	R: 5/5 L: 4/5
Shoulder abduction	R: 4+/5 L: 4+/5	R: 4/5 L: 4/5	R: 4/5 L: 4-/5	R: 5/5 L: 5/5
Shoulder Internal Rotation	R: 4+/5 L: 4+/5	R: 5/5 L: 5/5	R: 5/5 L: 5/5	R: 5/5 L: 5/5
Shoulder External Rotation	R: 4+/5 L: 4+/5	R: 4/5 L: 4/5	R: 4+/5 L: 4+/5	R: 4+/5 L: 4+/5
Scaption	-	R: 4/5 L: 4/5	R: 4/5 L: 4-/5	R: 4+/5 L: 4+/5
Elbow flexion	-	R: 5/5 L: 5/5	R: 4+/5 L: 4+/5	R: 5/5 L: 5/5
Elbow extension	-	R: 5/5 L: 5/5	R: 4+/5 L: 4+/5	R: 5/5 L: 5/5

**Table 6. Left Shoulder Passive Range of Motion Over Time**

	<b>Initial Examination</b>	<b>2 days before surgery</b>	<b>2 weeks after surgery</b>	<b>27 weeks after surgery</b>
<b>Shoulder Flexion</b>	168	180	172	176
<b>Shoulder Abduction</b>	166	180	110 with pain	178
<b>Shoulder ER</b>	95 (taken at 0 degrees abduction)	90	90	WNL
<b>Shoulder IR</b>	82	70	70	WNL

All values measured in degrees with a goniometer

ER = external rotation; IR = internal rotation; WNL = within normal limits.

### Outcomes

Outcome measures were recorded at several intervals culminating 27 weeks after surgery. Circumferential measurements were taken at the initial examination, two days before surgery, and then after surgery at three weeks, six weeks, 10 weeks, and 27 weeks. L-Dex scores were recorded at the initial examination, 10 weeks after surgery, and 27 weeks after surgery. The DASH was administered at the initial examination, 10 days after surgery, and 27 weeks after surgery. The FACIT-F was administered 10 days and 27 weeks post-operatively. The patient's strength and range of motion were recorded at the initial examination, two days before surgery, two weeks after surgery, and 27 weeks after surgery.

To further evaluate arm size over time, girth measurements were converted to volume. Due to the missing initial wrist girth, the authors calculated upper extremity volume using 16 cm as the initial value. This number was chosen to match the wrist measurement taken two days prior to surgery so as not to presume a change occurred between these two points in time. Based on the cutoff score established by the research, the patient had a meaningful improvement in limb volume two days prior to surgery compared to her initial examination values, indicating that CDT treatment was successful. After surgery, there was a trend of volumetric measurements increasing over time. Specifically, the data showed a meaningful increase in limb volume at six weeks and 27 weeks after surgery. In addition to increased arm volume, the patient's hand girth demonstrated a meaningful increase at 27 weeks compared to her initial examination.

The patient's L-Dex score indicated that she had a potentially meaningful increase in fluid in her

upper extremity both 10 weeks and 27 weeks after surgery compared to values obtained at her initial examination. There was not a meaningful change between 10 weeks and 27 weeks post-operation.

Based on her scores at the initial examination, we are 95 percent confident that 10 days after surgery, patient's change in self-reported DASH scores represented a meaningful decrease in upper extremity function. Twenty-seven weeks after surgery, the patient's score represented a clinically meaningful improvement when compared to her score taken 10 days after surgery. Although the patient's functional score reflected improvement at 27 weeks post surgery when compared to the initial examination, it did not represent a meaningful change.

The patient did not fill out a FACIT-F at her initial examination, so her score at 27 weeks post operation was compared to her score 10 days after surgery. Based on these values, we are 95 percent confident that the patient's FACIT-F change signified a potentially meaningful improvement in fatigue. Further information concerning outcome measures are recorded in tables 3 and 4 and in figure 8.

Manual muscle testing taken at the initial examination showed symmetrical 4+/5 shoulder strength bilaterally. Overall strength improved by up to ½ a testing grade 27 weeks after surgery and was symmetrical bilaterally. Table 5 details the change in strength over time.

At the initial examination, the patient's right arm range of motion was within functional limits, and deficits in left shoulder flexion, abduction, and external rotation are noted in Table 6. Two days before surgery, the patient had normal range for all examined motions. Two weeks after surgery, the patient had decreased

range in shoulder flexion and abduction accompanied by pain. By 27 weeks after surgery, the patient's motion was again normal, though the improvements were not meaningful.

Upon palpation, the patient's arm had increased fibrosis on her proximal forearm as well as scarring and excess fatty tissue on her wrist from the surgery at her 27-week follow up as compared to her initial examination.

## DISCUSSION

The purpose of this case report was to describe the outcomes of complete decongestive therapy focused on facilitating lymph fluid from proximal to distal in a patient with lymphedema who underwent a surgical lymph node transfer. After surgery, a Doppler was unable to detect adequate blood flow through the microsurgical anastomosis, prompting a second operation the following day. The second surgery succeeded in establishing tissue perfusion, but over the next several months the necrotic tissue at the wrist was surgically debrided several times. In all, the patient lost 60 percent of her wrist flap which may have been due to excess fat tissue with inadequate blood perfusion at the implant site. For six months after surgery, the patient was seen one to five times a week for physical therapy. She received education, manual lymph drainage, compression wrapping, and bilateral shoulder stretching and strengthening as well as a home maintenance program.

The patient's physical outcomes did not improve after surgery. In fact, her girth measurements were best pre-surgically after two weeks of conservative treatment. The patient's upper extremity volumetric data indicated a meaningful trend of increasing fluid, but these values may be inflated due to scarring and excess tissue at the surgical site. Seven of the patient's eight circumferential measurements were at least slightly higher than baseline, with three of them showing a meaningful increase in girth. Additionally, her L-DEX ratio revealed a clinically meaningful increase in fluid at both 10 and 27 weeks when compared to the initial examination.

The outcome measures generally trended toward a steady swelling in limb girth with stabilization over time. Ten weeks post surgery was the only date after the operation that reflected improvement in limb volume. When the upper extremity volume at 27 weeks

was compared to the volume at 10 weeks, there was a meaningful increase which may indicate that the patient's arm was continuing to swell. However, if the data point at 10 weeks was omitted, the patient's volume from 6 weeks to 27 weeks shows only a 69 mL increase, which did not surpass the threshold of meaningful change. When evaluated this way, the patient's volume appeared to plateau. Additionally, between weeks 10 and 27, the 7.1 unit increase in fluid recorded in the patient's L-Dex ratio was not meaningful, and it potentially indicated that the patient's lymphedema remained relatively steady despite weaning upper extremity wrapping and not wearing a compression garment.

Overall, the intervention of modified CDT to enhance lymph node transfer was not successful for this case report. The patient's premier goal was to maintain her existing arm girth without having to put forth the extensive effort required to regularly wrap her arm or wear a daily compression garment. A successful outcome was contingent upon having upper extremity volume remain less than or equal to the initial evaluation levels without needing daily compression therapy. Although her edema appeared to stabilize over time without wearing a compression sleeve, her volume at 27 weeks was 337.6 mL greater than her initial volume. Self-reported outcomes of upper extremity function and fatigue, as well as range of motion and strength all improved slightly, but the patient only had minimal impairments in these areas at the onset of the study. These improvements were not enough to compensate for overall worsening of lymphedema symptoms. The patient may have responded equally well or better if she hadn't been surgically treated and instead only conservative CDT treatment was employed with gradual weaning of compression therapy. The surgical intervention was expensive and can put patients at risk for developing donor site lymphedema. For these reasons, the authors determined the intervention was unsuccessful and they would not perform it in the future.

There were also several variables that were not constant, making it difficult to determine the true cause of the intervention's failure. Only 40 percent of the implanted lymph node tissue survived, which may have negatively impacted the surgery as well as the CDT treatment. The direction of CDT changed after surgery, and guiding lymph fluid against the body's



natural pressure gradients may have proved to be ineffective.

Previous research has reported favorable outcomes when continuing complete decongestive therapy for several months after surgery,<sup>7</sup> but there is a lack of evidence detailing how CDT might be modified to maximize the potential of a surgical flap that is located on the wrist. The study by Lin et al used the wrist as the recipient site and showed overall significant improvement in lymphedema symptoms, but it did not document any post operative CDT.<sup>8</sup> Other studies that included CDT after surgery had flaps located more proximally on the arm, so there was no need for the treatment to be modified.<sup>7</sup> Three studies included in this 2013 systematic review reported the participants were able to discontinue CDT within two years after lymph node transfer surgery.<sup>7</sup> Vascularized lymph node transfer is considered a newer treatment option in the United States. As this surgery gains popularity, it would be helpful for patients and therapists to have more information about the recovery process, including the best physical therapy interventions, the optimal time frame, and if it has the potential to be curative.

Although there were improvements in strength, range of motion, and subjective measures of fatigue and upper extremity function, the authors of

this case report would not change their clinical practice based on these results because the intervention did not succeed in reducing the patient's lymphedema. Research with a more rigorous study design should be conducted to determine if the same or better level of success could have been achieved with conservative treatment comprised of complete decongestive therapy without surgery. It is also vital to determine if the surgical intervention paired with standard protocol CDT that directs lymph toward the trunk would achieve more favorable results than CDT directed toward the wrist. The author proposes a randomized controlled trial comprised of three groups of participants with upper extremity lymphedema. There should be two experimental groups that underwent lymph node transfer surgery with the surgical flap located at the wrist. One group should include traditional CDT that guides lymph fluid toward the trunk, and the other would be composed of CDT that directs fluid toward the newly transplanted lymph nodes at the wrist. These groups would be compared to a control group that received only CDT without surgery.

This case report had several limitations. There was a small sample size with limited follow up, and outcome measures were not tracked at consistent intervals. Additionally, only 40 percent of the patient's surgical flap survived, which could have complicated the intervention's success.

## References

1. Ugur S. et al. Risk Factors of Breast Cancer-Related Lymphedema. *Lymphatic Research and Biology*. 2013. Jun;11(2) 72-5
2. Taylor, Richard. Jayasinghe, Upali. Koelmeyer, Jouse. Ung, Owen. Boyages, John. Reliability and Validity of Arm Volume Measurements for Assessment of Lymphedema. *PHYS THER*. 2006; 86:205-214.
3. Harris SR, Schmitz KH, Campbell KL, et al. Clinical practice guidelines for breast cancer rehabilitation: syntheses of guideline recommendations and qualitative appraisals. *Cancer*. 2012. 2312-2324.
4. National Lymphedema Network Medical Advisory Committee. The Diagnosis and Treatment of Lymphedema. NLN Position Paper: The Diagnosis And Treatment Of Lymphedema. 2013.
5. NLN Medical Advisory Committee. Position Paper: Training of Lymphedema Therapists. National Lymphedema Network. Nov. 2013.
6. McNeely, Margaret L et al. Conservative and Dietary Interventions for Cancer-Related Lymphedema A Systematic Review and Meta-Analysis. *Cancer* 2011;117:1136-48.
7. Penha, TR et al. Microsurgical techniques for the treatment of breast cancer-related lymphedema: a systematic review. *Journal of Reconstructive Microsurgery*. 2013. Feb;29(2):99-106.
8. Lin, Cheng-Hung et al. Vascularized Groin Lymph Node Transfer Using the Wrist as a Recipient Site for Management of Postmastectomy Upper Extremity Lymphedema. *Plastic and Reconstructive Surgery*. 2009. 1265 – 75.

9. Becker C, Assouad, J, Riguet, M, Hidden, G. Postmastectomy lymphedema: long-term results following microsurgical lymph node transplantation. *Ann Surg*. 2006. Mar;243(3):313-5.
10. Zuther, Joachim. *Lymphedema Management: The Comprehensive Guide for Practitioners*. New York: Thieme, 2009. 14-18, 114, 116-117, 122, 134, Print
11. Muir, Susan W et al. *Evaluating Change in Clinical Status: Reliability and Measures of Agreement for the Assessment of Glenohumeral Range of Motion*. *North A J Sports Phys Ther*, 2010 5, 3: 98 – 110
12. Mawdsley, Robert et al. Criterion-Related Validity of the Figure-of Eight Method of Measuring Ankle Edema. *J Ortho Sports Phys Ther* 2000; 30(3):149-153.
13. Fu, Mei et al. L-Dex ratio in Detecting Breast Cancer-Related Lymphedema: Reliability, Sensitivity, and Specificity. *Lymphology*. 2013. June ; 46(2): 85–96.
14. Dupeyron, Arnaud et al. Heterogeneous Assessment of Shoulder Disorders: Validation of the Standardized Index of Shoulder Function. *J Rehabil Med* 2010; 42: 967–972.
15. Harrington, Shana et al. Patient-Reported Shoulder Outcome Measures Utilized in Breast Cancer Survivors: A Systematic Review. *Arch Phys Med Rehabil*. 2014 January ; 95(1): 153–162.
16. Smoot, B et al. Upper Extremity Impairments in Women with or without Lymphedema Following Breast Cancer Treatment. *J Cancer Surv: Res Practice*. 2010 Jun;4(2):167-78.
17. Butt Z et al. Measurement of Fatigue in Cancer, Stroke, and HIV using the Functional Assessment of Chronic Illness Therapy – Fatigue (FACIT-F) Scale. *Psychosom Res*. 2013. Jan;74(1):64-8.
18. NLN Medical Advisory Committee. *Position Paper: Lymphedema Risk Reduction Practices*. *National Lymphedema Network*. May 2012. <http://www.lymphnet.org/resources/position-paper-lymphedema-risk-reduction-practices>.
19. Gunnesson, Christina et al. The Disabilities of the Arm, Shoulder and Hand (DASH) Outcome Questionnaire: Longitudinal Construct Validity and Measuring Self-rated Health Change After Surgery. *BMC Musculoskeletal Disorders*. 2003.
20. Cella, David et al. Validation of the Functional Assessment of Chronic Illness Therapy Fatigue Scale Relative to Other Instrumentation in Patients with Rheumatoid Arthritis. *J Rheumatol* 2005;32:811–9.